

Correction

DEVELOPMENTAL BIOLOGY

Correction for “Fourteen babies born after round spermatid injection into human oocytes,” by Atsushi Tanaka, Motoi Nagayoshi, Youichi Takemoto, Izumi Tanaka, Hiroshi Kusunoki, Seiji Watanabe, Keiji Kuroda, Satoru Takeda, Masahiko Ito, and Ryuzo Yanagimachi, which appeared in issue 47, November 24, 2015, of *Proc Natl Acad Sci USA* (112:14629–14634; first published November 2, 2015; 10.1073/pnas.1517466112).

The authors note that on page 14633, left column, second paragraph, lines 2–5, “The Institutional Review Boards of the Saint Mother Obstetrics and Gynecology Clinic and of the Ministry of Health, Labor, and Welfare of Japan approved this study on December 20, 2009 and July 3, 2011, respectively” should instead appear as “The Institutional Review Board of the Saint Mother Obstetrics and Gynecology Clinic approved this study on December 20, 2009 and approved the submission for the clinical trial registration on July 3, 2011.”

www.pnas.org/cgi/doi/10.1073/pnas.1606072113

Fourteen babies born after round spermatid injection into human oocytes

Atsushi Tanaka^{a,1}, Motoi Nagayoshi^a, Youichi Takemoto^a, Izumi Tanaka^a, Hiroshi Kusunoki^b, Seiji Watanabe^c, Keiji Kuroda^d, Satoru Takeda^d, Masahiko Ito^e, and Ryuzo Yanagimachi^{f,1}

^aSaint Mother Obstetrics and Gynecology Clinic, Institute for ART, Fukuoka 807-0825, Japan; ^bFaunal Diversity Sciences, Graduate School of Agriculture, Kobe University, Kobe 657-8501, Japan; ^cDepartment of Anatomical Science, Hirosaki University Graduate School of Medicine, Hirosaki 036-8562, Japan; ^dDepartment of Obstetrics and Gynecology, Juntendo University School of Medicine, Tokyo 113-0033, Japan; ^eDepartment of Infectious Diseases, Hamamatsu University School of Medicine, Hamamatsu 431-3192, Japan; and ^fDepartment of Anatomy, Physiology, and Biochemistry, University of Hawaii Medical School, Honolulu, HI 96822

Contributed by Ryuzo Yanagimachi, September 25, 2015 (sent for review July 20, 2015; reviewed by J. Michael Bedford and Martin M. Matzuk)

During the human *in vitro* fertilization procedure in the assisted reproductive technology, intracytoplasmic sperm injection is routinely used to inject a spermatozoon or a less mature elongating spermatid into the oocyte. In some infertile men, round spermatids (haploid male germ cells that have completed meiosis) are the most mature cells visible during testicular biopsy. The microsurgical injection of a round spermatid into an oocyte as a substitute is commonly referred to as round spermatid injection (ROSI). Currently, human ROSI is considered a very inefficient procedure and of no clinical value. Herein, we report the birth and development of 14 children born to 12 women following ROSI of 734 oocytes previously activated by an electric current. The round spermatids came from men who had been diagnosed as not having spermatozoa or elongated spermatids by andrologists at other hospitals after a first Micro-TESE. A key to our success was our ability to identify round spermatids accurately before oocyte injection. As of today, all children born after ROSI in our clinic are without any unusual physical, mental, or epigenetic problems. Thus, for men whose germ cells are unable to develop beyond the round spermatid stage, ROSI can, as a last resort, enable them to have their own genetic offspring.

human | round spermatid | ROSI | azoospermia | male infertility

Azoospermia, a condition in which there are no spermatozoa in the ejaculate, occurs in 1% of men in the general population (1). For men with obstructive azoospermia, microsurgical aspiration of epididymal spermatozoa has been performed, and the pregnancy rate following injection of oocytes with epididymal spermatozoa is comparable to that following injection of ejaculated spermatozoa (2). However, up to 94% (17 of 18) of azoospermic men are diagnosed as having nonobstructive azoospermia (3). For such men, microscopic testicular sperm extraction (micro-TESE) has been widely performed to obtain testicular spermatozoa, which are reportedly found in up to 60% of all such cases (4–7). When neither spermatozoa nor late-stage spermatids are found in the testes, such men are considered sterile and are advised to consider using a sperm donor. However, clinicians should consider another possibility: the injection of round spermatids into oocytes. In our clinic, we have found that about 30% of nonobstructive azoospermic men with neither spermatozoa nor late-stage spermatids did possess round spermatids (8), and that such germ cells can be used as a last resort.

In an earlier investigation, Ogura and Yanagimachi (9) found that hamster round spermatids electro-fused with oocytes formed pronuclei, which could participate in syngamy. Subsequently, they reported the birth of normal mouse offspring following microsurgical injection of round spermatids (ROSI) (10, 11). Male mice homologous for a mutation in the cAMP responsive-element modulator gene (*Crem*) are unable to undergo spermiogenesis, and therefore the most advanced spermatogenic cells present in such males are round spermatids (12). According to Yanagimachi et al. (13), round spermatids collected from the testes of such *Crem*-null males were able to produce fertile offspring following

their injection into mature oocytes. The idea of using spermatids as substitutes for spermatozoa in humans was first proposed by Edwards et al. (14). Since the first ROSI human babies were obtained by Tesarik et al. (15, 16), additional pregnancies have been reported (17–19). However, there have been very few similar reports in recent years, perhaps because many clinical investigators have become pessimistic as to the efficiency, safety, and practical value of ROSI (20–23). Indeed, both the Practice Committee of American Society for Reproductive Medicine and the Practice Committee of Society for Assisted Reproductive Technology (24) considered ROSI as an experimental rather than a recommended practice. In an attempt to take this further, we tried to obtain spermatozoa by culturing human primary spermatocytes *in vitro*. Although some spermatocytes developed into round spermatids, they did not develop further (25), and attempts to transform round spermatids into spermatozoa *in vitro* met with limited success (8). Therefore, when we did not find normal-looking spermatozoa or late spermatids in micro-TESE, we used the round spermatids from the patients for the ROSI. Here, we report the details of the ROSI procedure that lead to the birth of 14 babies born between September 2011 and March 2014.

Results

Identification of Round Spermatids. When we failed to find spermatozoa or elongated spermatids but found presumptive round spermatids, all seminiferous tubules thus far collected were enzymatically dissociated and kept frozen until their use for ROSI

Significance

Men without spermatozoa or elongating spermatids in their testes have been considered sterile and are advised to consider using a sperm donor. However, these men may have round spermatids. We have been able to accurately identify these cells based on their structural and physical characteristics (verified by karyotyping and FISH). Round spermatid injection was effectively used in our clinic and resulted in the birth of 14 healthy babies. Although the current success rate of round spermatid injection is not very high compared with intracytoplasmic sperm injection, this procedure can be the last resort for men who cannot produce spermatozoa but wish to use their own genetic material to produce offspring.

Author contributions: A.T. designed research; A.T., M.N., Y.T., I.T., S.W., and S.T. performed research; K.K. contributed new reagents/analytic tools; A.T., H.K., M.I., and R.Y. analyzed data; and A.T. and R.Y. wrote the paper.

Reviewers: J.M.B., Weill Medical College, Cornell; and M.M.M., Baylor College of Medicine. The authors declare no conflict of interest.

Freely available online through the PNAS open access option.

¹To whom correspondence may be addressed. Email: incho@stmother.com or yana@hawaii.edu.

This article contains supporting information online at www.pnas.org/lookup/suppl/doi:10.1073/pnas.1517466112/-DCSupplemental.

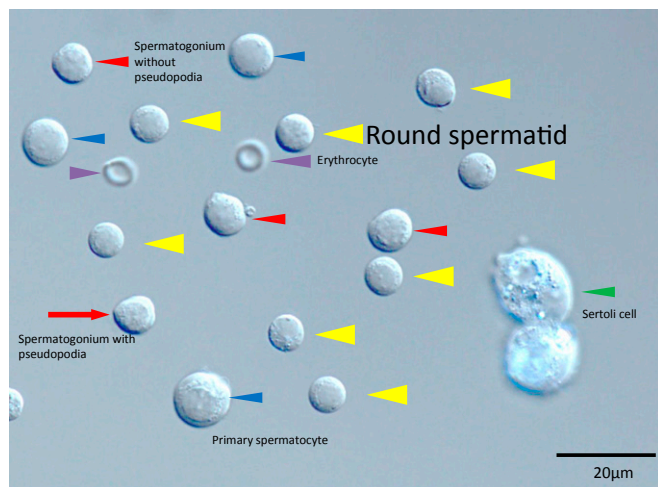


Fig. 1. Various types of spermatogenic cells seen after enzymatic dissociation of seminiferous tubules. (Magnification: 400 \times .) A few erythrocytes (purple arrowheads) with a distinct shape are also seen (we treated dissected seminiferous tubules with erythrocyte-lysing buffer, but some cells remained nonlysed). Spermatogonia with or without pseudopodia (red arrows and red arrowheads), primary spermatocytes (blue arrowheads), round spermatids (yellow arrowheads), and Sertoli cells (green arrowhead) are seen.

(for details, see *Materials and Methods* and *SI Materials and Methods*). Thawed samples contained various types of cells (Fig. 1 and Fig. S1). Under a differential interference microscope, we identified round spermatids by their size and morphology (Fig. 2). FISH and karyotyping of these cells confirmed that our optical identification of round spermatids was fairly accurate (Figs. 2 and 3).

As shown in Fig. 2, round spermatids were the smallest spermatogenic cells (6–8 μm in diameter). Unlike other spermatogenic cells, they did not have distinct nucleoli and the rim of cytoplasm surrounding the nucleus was thinner than that in the spermatogonium. Protruded active pseudopodia were often seen in spermatogonia (26), but not in round spermatids. An acrosome vesicle or cap, definitive evidence for the cell being a spermatid, was seen in less than 10% of the presumptive spermatids we examined. Another important characteristic of the round spermatid was evident in the fact that its cytoplasm could be readily separated from the nucleus when the cell was drawn back and forth within the injection pipette. Thus, although some spermatogonia did resemble round spermatids, pipetting did not separate their cytoplasm from the nucleus as readily as in spermatids. Lymphocytes, about the size of round spermatids, had a “tough” plasma membrane that, unlike that of round spermatids, could not be broken even by vigorous pipetting.

ROSI and Oocyte Activation. Fig. 4 shows an oocyte injected with a round spermatid whose plasma membrane ruptured when the cell was sucked into the injection pipette (Fig. 4B). Although ROSI alone could induce oocyte activation, this outcome was not consistent. Therefore, because repetitive intracellular Ca^{2+} oscillations are an essential component of oocyte activation and a prerequisite of normal embryo development (27), we compared the pattern of Ca^{2+} oscillations in oocytes after vigorous ooplasmic aspiration (16), electric stimulation, ROSI, and ROSI plus electric stimulation. As shown in Fig. S2, ROSI combined with electric stimulation (Fig. S2D) was most effective in inducing large, repetitive Ca^{2+} oscillations. Because our previous study had shown that oocytes stimulated with electric current before ROSI developed into cleaving embryos more often than those without such treatment (55% vs. 32%) (Table S1), we subjected all oocytes to electro-stimulation ~ 10 min before ROSI. An example of ROSI embryo developing in vitro after this stimulation is shown in Fig. S3.

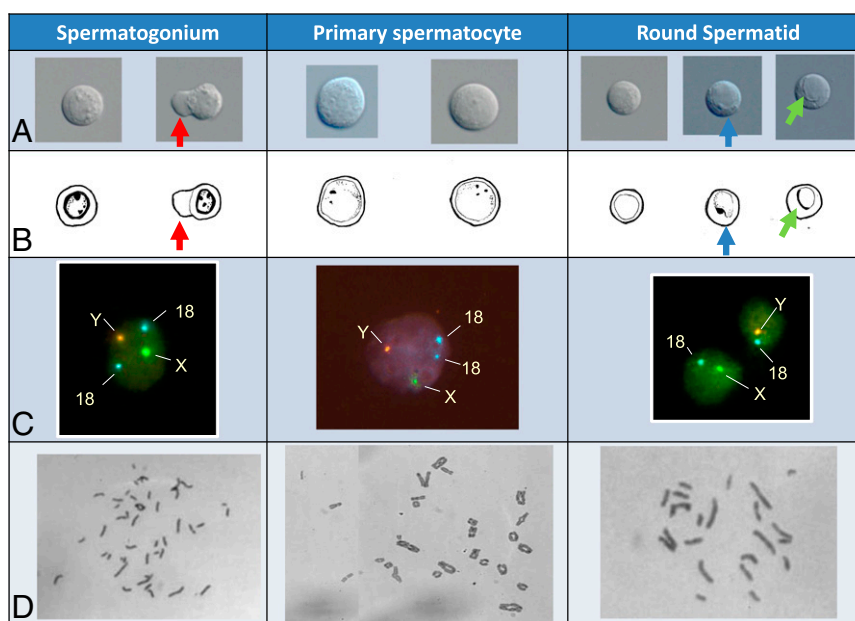


Fig. 2. Spermatogonia, primary spermatocytes, and round spermatids, (A) seen with interference-contrast optics, and (B) their schematic drawings. (Magnification: A, 400 \times .) (C) FISH using fluorescent probes specific for chromosomes X, Y, and 18. (Magnification: 400 \times .) (D) Giemsa-stained chromosome spreads. (Magnification: 200 \times .) A spermatogonium with diploid (46) chromosomes is characterized by the presence of two to three nucleoli adjacent to a clearly visible nuclear envelope. Some spermatogonia have pseudopodia (red arrow in A). The spermatogonium shown here has two chromosomes 18, and one X and one Y chromosome. Primary spermatocytes are the largest cells, with two to three small nucleoli and tetrad chromosomes characteristic of meiotic cells. Each cell has two spots for chromosome 18 and one X and one Y. The small round spermatid has an indistinct nuclear membrane, and each has a haploid set of chromosomes (23), one chromosome 18 and either one X or one chromosome Y chromosome. Only about 10% of round spermatids examined showed an acrosome vesicle (blue arrow in A) or acrosome cap (green arrow in A).

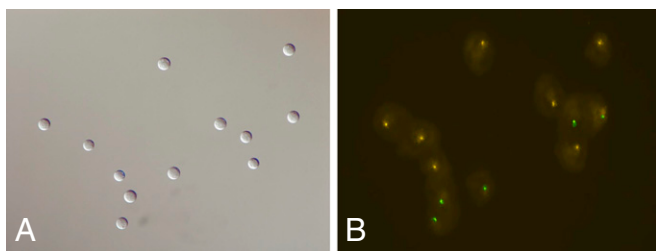


Fig. 3. (A) Twelve presumptive round spermatids randomly selected and adherent to a glass slide. (B) The same cells after FISH, each showing a single spot of either chromosome X (green) or Y (orange). (Magnification: A and B, 400 \times .)

Live Birth of Healthy Babies Following ROSI. Table 1 summarizes the results of embryo transfer after ROSI. To compare the efficiency of ROSI with that of intracytoplasmic sperm injection (ICSI), part of the data collected in our clinic after TESE and ICSI (28, 29). Currently, ROSI is less efficient than ICSI in obtaining live offspring. Note that in both ROSI and ICSI, embryos that had been kept frozen before transfer to mothers had better chance to develop to term than those that had not been frozen ($P < 0.05$).

Table 2 summarize patients' information, developmental stages of embryos at the time of transfer, karyotypes, and gender of fetuses, and the growth data of babies born after ROSI. As shown in Table 2, all 14 babies were karyotypically normal. The mean (\pm SD) gestational age and body weight at birth were 38.5 wk (± 1.19 , $n = 12$ deliveries) and 2,832.8 g (± 497.0 , $n = 14$ babies), respectively. Pathological examination of all miscarriages following ROSI revealed no partial or complete hydatidiform moles. As of today, all children born after ROSI are growing well without any physical or mental problems and with no evidence of Prader-Willi syndrome, Angelman syndrome, or Wiskott-Aldrich syndrome or any other unusual physical and mental aberrations.

Discussion

The Use of ROSI in Cases of Spermatogenetic Arrest at the Round Spermatid Stage. Silber et al. (21) maintain that whenever round spermatids exist in the human testes, there are also mature spermatozoa present. In other words, there is no spermatogenesis arrest at the spermatid stage. Clearly this is not the case for animals. For example, the testes of mutant male mice homologous for the *Crem* gene are devoid of spermatozoa, the most advanced spermatogenic cells in these males being round spermatids. Although these males are, of course, infertile (12, 30), ROSI can help to

overcome this problem (13). According to He et al. (31), human males with *Crem* gene variants are also azoospermic, with the most advanced spermatogenic cells in such men being round spermatids. Moreover, Weinbauer et al. (32) reported the importance of *Crem* protein for the initiation of human spermiogenesis. In mice, *Crem* is an autosomal recessive gene, and therefore when spermatids of *Crem*-null males were injected into oocytes of wild-type (*Crem*^{+/+}) females, all male offspring were fertile (13). This was true for mutant mice lacking such genes as *bs* (blind-sterile) (13), ring finger protein 17 (*RNF17*), CUG triplet repeat, RNA binding protein 1 (*Cugbp1*), and jumonji domain-containing 1a (*Jmjd1a*) (33–36). According to Ayhan et al. (37), in men with mutations of two autosomal recessive genes, *TAF4B* and *ZMYND15*, their spermatogenesis is arrested at the round spermatid stage. It would be interesting to know if their specific type of infertility can be overcome by ROSI.

Table 2 includes histology-based Johnsen's scores (38) of the 12 men who participated in this study. Note that the husband of wife 1 had a Johnsen's score of 1 after initial histological examination of testis biopsies. This meant that neither spermatogenic cells nor Sertoli cells were found in biopsied samples (Fig. S4A). However, later examination of other portions of the samples revealed spermatid-like cells within some of the tubules (Fig. S4B). Intensive searches for spermatozoa and spermatogenic cells in the testis eventually made it possible for us to find spermatids suitable for ROSI. Johnsen's scores (38), which are solely dependent upon histological examination of seminiferous tubules collected from very limited regions of the testis, should be considered as merely representing the predominant pattern of spermatogenesis (39).

Possible Reasons for Previous Failures of Human ROSI. In the mouse, identification of round spermatids is not difficult because they exhibit a distinct centrally located chromatin granule observed readily under the interference-contrast microscope used for microsurgical operation of oocytes (40). Round spermatids are the smallest spermatogenic cells in the testis and can be readily distinguished from small blood cell leukocytes. In contrast to the mouse, human spermatids do not show a distinct chromatin granule, at least under an inverted microscope with Hoffman modulation contrast optics. It is very likely that many previous investigators, who attempted ROSI, actually chose the wrong cells in that one cannot expect normal development of oocytes injected with spermatogonia or somatic cells. Nuclei of spermatocytes (tetraploid or diploid) cannot participate in embryo development

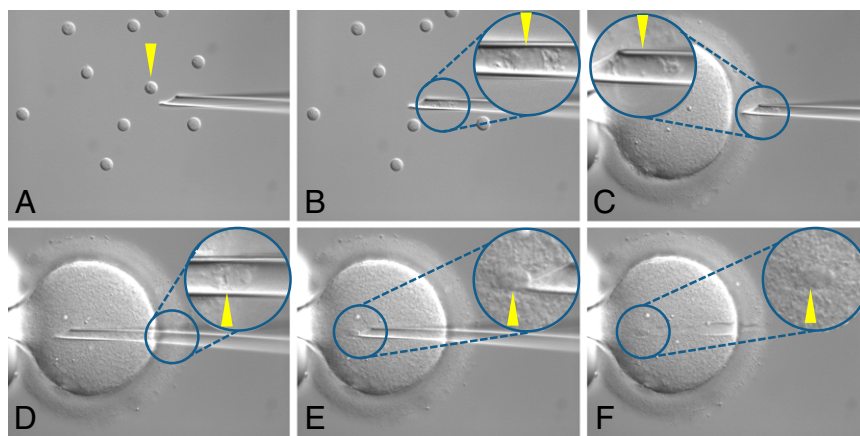


Fig. 4. The procedure of ROSI. (A) Immediately before picking up one spermatid. (B) A spermatid aspirated into the injection pipette, the plasma membrane being broken. The white arrowhead indicates the spermatid nucleus. (C–F) Oocytes before, during and after injection of spermatid. Arrowhead indicates the spermatid nucleus. (Magnification: A–F, 400 \times .)

Table 1. Clinical outcome of ROSI partners of 76 women in this table had round spermatids as their most advanced spermatogenic cells

Assisted fertilization	Cryopreservation of embryos	Total no. of women	Total no. of treatment cycles	Percentage of oocytes fertilized (fert/total) (%)	Percentage Oocytes cleaved (cleaved/total) (%)	Total no. of transferred embryos	No. and percentage of recipients (%)					Total no. of live offspring
							Total transferred cycles	Pregnancy*	Miscarriage	Live offspring delivered	Total no. of live offspring	
ROSI (present study)	No	58	162	55.6 (330/594)	44.9 (267/594)	152	121	20 (16.5)	13 (65.0)	7 (5.8) ^{§§}	9	
	Yes	28 [†]	42	76.4 (107/140)	71.4 (100/140)	56	42	10 (23.8)	5 (50.0)	5 (11.9) [¶]	5	
TESE and ICSI	No	260	540	44.9 (833/1855)	43.5 (807/1,855)	562	468	134 (28.6)	27 (20.1)	107 (22.9) [§]	121	
	Yes	140	295	68.2 (825/1210)	65.3 (790/1,210)	377	290	174 (60.0)	14 (8.0)	160 (55.2) ^{§§, ¶¶}	176	

Partners of 76 women in this table had round spermatids as their most advanced spermatogenic cells. To compare the efficiencies of ROSI and ICSI, part of the data collected in our clinic after TESE and ICSI are included in this table. § vs. §§ and ¶ vs. ¶¶, $P < 0.05$; Fisher's protected least significant difference test. *No and percentage of recipients with positive germinal sacs detected by ultrasound scanning between 4 and 5 wk of gestation.

[†]Ten of these 28 patients failed to get pregnancy previously when they received nonfrozen ROSI embryos.

without first completing meiosis within oocytes, which is very difficult, if not impossible (40–42). An acrosome vesicle or acrosomal cap detected on the nucleus of small round cells indicates that they are round spermatids. However, the absence of such structures does not mean that the cell in question is not an early-stage round spermatid. Even though FISH and karyotyping are a reliable means through which to identify them, we cannot use such invasive techniques for ROSI, which requires live cells. The day may come when we can identify round live spermatids correctly by using an antibody specific to their surface. Computer-assisted identification of live spermatids and other types of spermatogenic cells may become available in the near future.

Another reason for the failure of many attempts using ROSI could be because of incomplete activation of the recipient oocytes, despite the fact that human round spermatids may contain at least some oocyte-activating ability (43). According to Ogonuki et al. (44), fresh round spermatids injected into mouse oocytes were unable to activate oocytes, whereas spermatids frozen and thawed before injection could do so, suggesting that some endogenous oocyte-activating factor is mobilized by the freeze–thawing routinely used in this study. Although round spermatid injection alone could induce small Ca^{2+} oscillations (Fig. S2C), ROSI with prior

electrical stimulation was most effective in inducing repetitive, large Ca^{2+} oscillations (Fig. S2D). We need further systematic studies to identify the best method to activate human ROSI oocytes. Other oocyte-activating agents to be considered include: Ca^{2+} ionophore (20, 45, 46), phosphatidyl inositol (47, 48), phospholipase C ζ (49–51), 4- (diethylamino) pyridine (52), and post-acrosomal protein PAWP (53–55).

Interestingly, pregnancy and delivery rates following ROSI were higher when embryos were first kept frozen for some time as opposed to their transfer soon after ROSI (Table 1). Because this was true for ICSI (Table 1), it was perhaps because of better preparation of the uterine endometrium when recipients were allowed to resume their normal ovulation cycle before transfer.

Safety of ROSI. The safety of any of the assisted fertilization technologies is a prime concern. Some investigators suspect that the inefficacy of ROSI might be because of incomplete male-specific DNA methylation imprinting in round spermatids, but at least in the mouse, DNA methylation is completed in round spermatids (56) and even before meiosis begins (57). One possible factor might be the inefficient demethylation and remethylation of DNA after introduction of spermatid nuclei into mature oocytes (58).

Table 2. Clinical data of 14 offspring developed from ROSI oocytes

Case	Parents			Data from ROSI to embryo transfer					Data of birth			Medical check up											
	Age (years)		Initial Husband at TESE	Wife Johnsen's Score* in TESE	Percent Oocytes fertilized (fert/total) (%)	Developmental stage × No. of embryos transferred	Embryo transferred	Karyotype of fetus	Mode of delivery	No. of live offspring	Gestational weeks	Gender	1 mo		6 mo		1 y		1.5 y		2 y		
	at TESE	ROSI											BW	BW	PCD	BW	PCD	BW	PCD	BW	PCD	BW	PCD
1	37	36	1	33.3 (2/6)	8 cell ×2	Fresh	46XX	Vaginal	1	F	41	2876	3728	N	7745	N	ND	ND	10000	N	ND	ND	
2	28	28	1	50.0 (9/18)	8 cell ×2	Cryopreservation	46XX	Vaginal	1	F	39	3224	4438	N	ND	ND	ND	9800	N	ND	ND	ND	
3	34	37	3	50.0 (1/2)	Blastocyst ×1	Fresh	46XY	C-section	2 [†]	M	36	2340	2640	N	8340	N	9360	N	10800	N	11750	N	
4	36	32	6	50.0 (5/10)	10 cell ×1+ Morula ×1	Fresh	46XY	Vaginal	1	M	39	3440	4115	N	ND	ND	ND	ND	ND	ND	ND	—	—
5	40	39	4	65.0 (13/20)	11 cell ×1+ Morula ×1	Cryopreservation	46XY	C-section	1	M	38	2598	3490	N	ND	ND	8305	N	—	—	—	—	
6	28	28	7	50.0 (7/14)	5 cell ×2	Fresh	46XX	Vaginal	1	F	38	3115	4255	N	9240	N	9480	N	—	—	—	—	
7	34	39	3	75.0 (3/4)	12 cell ×2	Fresh	46XY	Vaginal	2 [†]	M	37	2666	4080	N	9790	N	9855	N	—	—	—	—	
8	36	35	7 [§]	50.0 (2/4)	Morula ×1+ Blastocyst ×1	Cryopreservation	46XY	Vaginal	1	M	39	3348	4596	N	9500 [¶]	N	—	—	—	—	—	—	
9	26	23	6	42.1 (8/19)	8 cell ×2	Cryopreservation	46XX	Vaginal	1	F	38	2834	4145	N	7805	N	—	—	—	—	—	—	
10	38	37	7	23.1 (3/13)	10 cell ×2	Fresh	46XY	Vaginal	1	M	39	2776	3378	N	6105	N	—	—	—	—	—	—	
11	41	40	7	93.8 (15/16)	8 cell ×2	Fresh	46XY	Vaginal	1	M	39	2080	2945	N	—	—	—	—	—	—	—	—	
12	43	34	7	56.3 (9/16)	Blastocyst ×1	Cryopreservation	46XY	Vaginal	1	M	39	3748	4920 ^{**}	N	—	—	—	—	—	—	—	—	

BW, body weight (g); F, female; M, male; N, normal; ND, No data; PCD, physical and cognitive development.

*Johnsen (38).

[†]Monozygotic twins.

[‡]Dizygotic twins, ^{**}3 mo, [¶]9 mo, ^{||}7 mo.

[§]Examination of biopsied sample and re-examination of histology slide revealed the presence of few highly deformed elongated spermatids, but we did not use these cells for this study because they were not tolerant to freeze–thawing the procedure we used routinely for ROSI.

Tricostatin A, an inhibitor of histone deacetylase, which significantly reduces abnormal DNA hypermethylation in somatic cell nuclei transplanted into enucleated oocytes (59), may increase the success rate of human ROSI. Even though all 14 babies born after ROSI are healthy and have no unusual physical or mental problems, because the number of successful case is still small, it might be premature to conclude that conception after ROSI is as safe as in vitro fertilization or ICSI. However, it is likely that the ROSI procedures can be further refined. For example, in most animals, the sperm centrosome plays a crucial role in normal fertilization as the center of the microtubular assembly (sperm aster), which is essential for the approximation and fusion of male and female pronuclei (60, 61). It is also possible that centrosomes in some of the round spermatids we used were “immature.” If this proves to be the case, the replacement of an immature centrosome by a mature centrosome, as proposed for ICSI by Nakamura et al. (62), may increase the efficiency of ROSI.

Materials and Methods

Ethical Aspects. This study was conducted with the informed consent of all participating patients. The Institutional Review Boards of the Saint Mother Obstetrics and Gynecology Clinic and of the Ministry of Health, Labor, and Welfare of Japan approved this study on December 20, 2009 and July 3, 2011, respectively. This study was registered and adhered to International Committee of Medical Journal Editors criteria. The University Hospital Medical Information Network Clinical Trials Registry is UMIN000006117.

Subjects. We conducted Micro-TESE on 730 nonobstructive azoospermic men who had already undergone a previous Micro-TESE conducted by andrologists from other institutions and had been found not to have normal spermatogenic cells beyond the round spermatid stage. We found round spermatids in 76 (10.4%) of the 730 men. These 76 men, aged 22–46 y (33.4 ± 5.2), participated in a total of 163 transfer cycles in our clinic between September 2011 and March 2014.

Collection and Cryopreservation of Spermatogenic Cells from Azoospermic Men.

Testicular tubular biopsies (20–50 mg each) were obtained from not only the surface, but also from deep inside the testis until we found spermatozoa

or elongated spermatids. If no such cells were found despite our continuing efforts, but we saw many normal-looking spermatids, all collected tubules were dissociated enzymatically and cryopreserved. Details are provided in *SI Materials and Methods*.

Thawing of Frozen Testicular Cell Samples and Identification of Round Spermatids Immediately Before ROSI.

Thawing was carried out at 30 °C. Using a differential interference microscope, morphological and physical features of individual cells were examined. Their small size (6–8 μm in diameter), thin rim of cytoplasm around the nucleus, and ready separation of cytoplasm from the nucleus were important identifying features of round spermatids. The accuracy of the visual identification was checked by karyotyping and FISH, which proved to be near 100%. Details are provided in *SI Materials and Methods*.

Collection and Activation of Oocytes Before ROSI.

Mature oocytes (at metaphase II), collected from ovaries 36 h after hCG injection (63), were maintained for 5–7 h in HFT medium (64) before their activation by either ooplasm aspiration (16) or electronic stimulation (65). ROSI was performed 10 min later. In some experiments, changes in intracellular Ca^{2+} concentration were monitored using a Ca^{2+} -sensitive fluorescence indicator. Details are provided in *SI Materials and Methods*.

ROSI and Embryo Transfer. A presumptive spermatid, selected on the basis of its morphological and physical features, was injected into an oocyte. One or two oocytes reaching the four-cell to blastocyst stage were transferred to the uterus and pregnancy was assessed 4–5 wk later. Details are provided in *SI Materials and Methods*.

Statistical Analysis. Data were analyzed using the Microsoft Excel Add-in software (MacToukei-kaiseki v2.0; Esumi).

ACKNOWLEDGMENTS. We thank Drs. Atsuo Ogura (Riken), Wei Yan (University of Nevada), Edward M. Eddy (National Institutes of Health), Bernard Robaire (McGill University), and Jean-Pierre Ozil (Institut National de la Recherche Agronomique) for providing invaluable information and advice; and Mr. Roberto Rodriguez, Dr. J. Michel Bedford (Cornell University), and Dr. Martin M. Matzuk (Baylor College of Medicine) for their generous help in the preparation of this manuscript.

- Willott GM (1982) Frequency of azoospermia. *Forensic Sci Int* 20(3):9–10.
- Jarvi K, et al. (2010) CUA guideline: The workup of azoospermic males. *Can Urol Assoc J* 4(3):163–167.
- Patrizio P, Silber S, Ord T, Balmaceda JP, Asch RH (1988) Two births after microsurgical sperm aspiration in congenital absence of vas deferens. *Lancet* 2(8624):1364.
- Schlegel PN, Girardi SK (1997) Clinical review 87: In vitro fertilization for male factor infertility. *J Clin Endocrinol Metab* 82(3):709–716.
- Schlegel PN, Su L-M (1997) Physiological consequences of testicular sperm extraction. *Hum Reprod* 12(8):1688–1692.
- Schlegel PN, et al. (1997) Testicular sperm extraction with intracytoplasmic sperm injection for nonobstructive azoospermia. *Urology* 49:435–440.
- Ashraf MC, Singh S, Raj D, Ramakrishnan S, Esteves SC (2013) Micro-dissection testicular sperm extraction as an alternative for sperm acquisition in the most difficult cases of Azoospermia: Technique and preliminary results in India. *J Hum Reprod Sci* 6(2):111–123.
- Tanaka A, et al. (2006) In vitro culture of the immature spermatogenic cells. *Fertil Steril* 86(Suppl):S518–S519.
- Ogura Y, Yanagimachi R (1993) Round spermatid nuclei injected into hamster oocytes from pronuclei and participate in syngamy. *Biol Reprod* 48(2):219–225.
- Ogura A, Matsuda J, Yanagimachi R (1994) Birth of normal young after electrofusion of mouse oocytes with round spermatids. *Proc Natl Acad Sci USA* 91(16):7460–7462.
- Kimura Y, Yanagimachi R (1995) Mouse oocytes injected with testicular spermatozoa or round spermatids can develop into normal offspring. *Development* 121(8):2397–2405.
- Nantel F, et al. (1996) Spermiogenesis deficiency and germ-cell apoptosis in CREM-mutant mice. *Nature* 380(6570):159–162.
- Yanagimachi R, et al. (2004) Production of fertile offspring from genetically infertile male mice. *Proc Natl Acad Sci USA* 101(6):1691–1695.
- Edwards RG, Tarin JJ, Dean N, Hirsch A, Tan SL (1994) Are spermatid injections into human oocytes now mandatory? *Hum Reprod* 9(12):2217–2219.
- Tesarik J, Mendoza C (1996) Spermatid injection into human oocytes. I. Laboratory techniques and special features of zygote development. *Hum Reprod* 11(4):772–779.
- Tesarik J, et al. (1996) Spermatid injection into human oocytes. II. Clinical application in the treatment of infertility due to non-obstructive azoospermia. *Hum Reprod* 11(4):780–783.
- Gianaroli L, et al. (1999) Birth of a healthy infant after conception with round spermatids isolated from cryopreserved testicular tissue. *Fertil Steril* 72(3):539–541.
- Vanderzwalmen P, et al. (1997) Intracytoplasmic injection of spermatids retrieved from testicular tissue: Influence of testicular pathology, type of selected spermatids and oocyte activation. *Hum Reprod* 12(6):1203–1213.
- Barak Y, et al. (1998) Pregnancy and birth after transfer of embryos that developed from single-nucleated zygotes obtained by injection of round spermatids into oocytes. *Fertil Steril* 70(1):67–70.
- Van Der Zwalm P, et al. (1995) Fertilization of an oocyte microinseminated with a spermatid in an in-vitro fertilization programme. *Hum Reprod* 10(3):502–503.
- Silber SJ, Johnson L, Verheyen G, Van Steirteghem A (2000) Round spermatid injection. *Fertil Steril* 73(5):897–900.
- Silber SJ, Johnson L (1998) Are spermatid injections of any clinical value? ROSNI and ROSI revisited. Round spermatid nucleus injection and round spermatid injection. *Hum Reprod* 13(3):509–515.
- Vanderzwalmen P, et al. (1998) Is there a future for spermatid injections? *Hum Reprod* 13(Suppl 4):71–84.
- Practice Committee of American Society for Reproductive Medicine; Practice Committee of Society for Assisted Reproductive Technology (2008) Round spermatid nucleus injection (ROSNI). *Fertil Steril* 90(5, Suppl):S199–S201.
- Tanaka A, et al. (2003) Completion of meiosis in human primary spermatocytes through in vitro coculture with Vero cells. *Fertil Steril* 79(Suppl 1):795–801.
- Tanaka A, et al. (2008) Isolated spermatogonia protrude active pseudopodia in vitro. *Fertil Steril* 90(2):453–455.
- Ozil JP, Banrezes B, Tóth S, Pan H, Schultz RM (2006) Ca^{2+} oscillatory pattern in fertilized mouse eggs affects gene expression and development to term. *Dev Biol* 300(2):534–544.
- Tanaka A, Nagayoshi M, Awarta S, Himeno I, Tanaka I (2008) Improvement of a photodynamic system for observation of seminiferous tubules in microdissection-testicular sperm extraction (MD-TESE). *Fertil Steril* 90:S106.
- Yamaguchi T, et al. (2014) Comparative study of obstructive azoospermia with MESE or MD-TESE. *Obstet Gynecol Pract* 63(6):881–885.
- Blendy JA, Kaestner KH, Weinbauer GF, Nieschlag E, Schütz G (1996) Severe impairment of spermatogenesis in mice lacking the CREM gene. *Nature* 380(6570):162–165.
- He XJ, et al. (2014) CREM variants rs4934540 and rs2295415 conferred susceptibility to nonobstructive azoospermia risk in the Chinese population. *Biol Reprod* 91(2):52.
- Weinbauer GF, Behr R, Bergmann M, Nieschlag E (1998) Testicular cAMP responsive element modulator (CREM) protein is expressed in round spermatids but is absent or reduced in men with round spermatid maturation arrest. *Mol Hum Reprod* 4(1):9–15.

33. Pan J, et al. (2005) RNF17, a component of the mammalian germ cell nuage, is essential for spermiogenesis. *Development* 132(18):4029–4039.
34. Kress C, Gautier-Courteille C, Osborne HB, Babinet C, Paillard L (2007) Inactivation of CUG-BP1/CELF1 causes growth, viability, and spermatogenesis defects in mice. *Mol Cell Biol* 27(3):1146–1157.
35. van der Weyden L, et al. (2006) Loss of TSLC1 causes male infertility due to a defect at the spermatid stage of spermatogenesis. *Mol Cell Biol* 26(9):3595–3609.
36. Liu Z, et al. (2010) Jmjd1a demethylase-regulated histone modification is essential for cAMP-response element modulator-regulated gene expression and spermatogenesis. *J Biol Chem* 285(4):2758–2770.
37. Ayhan Ö, et al. (2014) Truncating mutations in TAF4B and ZMYND15 causing recessive azoospermia. *J Med Genet* 51(4):239–244.
38. Johnsen SG (1970) Testicular biopsy score count—A method for registration of spermatogenesis in human testes: Normal values and results in 335 hypogonadal males. *Hormones* 1(1):2–25.
39. Berookhim BM, Palermo GD, Zaninovic N, Rosenwaks Z, Schlegel PN (2014) Microdissection testicular sperm extraction in men with Sertoli cell-only testicular histology. *Fertil Steril* 102(5):1282–1286.
40. Kimura Y, Yanagimachi R (1995) Development of normal mice from oocytes injected with secondary spermatocyte nuclei. *Biol Reprod* 53(4):855–862.
41. Kimura Y, Tateno H, Handel MA, Yanagimachi R (1998) Factors affecting meiotic and developmental competence of primary spermatocyte nuclei injected into mouse oocytes. *Biol Reprod* 59(4):871–877.
42. Ogura A, et al. (1998) Development of normal mice from metaphase I oocytes fertilized with primary spermatocytes. *Proc Natl Acad Sci USA* 95(10):5611–5615.
43. Yazawa H, Yanagida K, Sato A (2007) Human round spermatids from azoospermic men exhibit oocyte-activation and Ca²⁺ oscillation-inducing activities. *Zygote* 15(4):337–346.
44. Ogonuki N, Inoue K, Ogura A (2011) Birth of normal mice following round spermatid injection without artificial oocyte activation. *J Reprod Dev* 57(4):534–538.
45. Steinhardt RA, Epel D, Carroll EJ, Jr, Yanagimachi R (1974) Is calcium ionophore a universal activator for unfertilized eggs? *Nature* 252(5478):41–43.
46. Sousa M, Mendoza C, Barros A, Tesarik J (1996) Calcium responses of human oocytes after intracytoplasmic injection of leukocytes, spermatocytes and round spermatids. *Mol Hum Reprod* 2(11):853–857.
47. Miyazaki S (1988) Inositol 1,4,5-trisphosphate-induced calcium release and guanine nucleotide-binding protein-mediated periodic calcium rises in golden hamster eggs. *J Cell Biol* 106(2):345–353.
48. Amano T, Mori T, Watanabe T (2004) Activation and development of porcine oocytes matured in vitro following injection of inositol 1,4,5-trisphosphate. *Anim Reprod Sci* 80(1–2):101–112.
49. Nomikos M, Kashir J, Swann K, Lai FA (2013) Sperm PLC ζ : From structure to Ca²⁺ oscillations, egg activation and therapeutic potential. *FEBS Lett* 587(22):3609–3616.
50. Ito M, Shikano T, Kuroda K, Miyazaki S (2008) Relationship between nuclear sequestration of PLC ζ and termination of PLC ζ -induced Ca²⁺ oscillations in mouse eggs. *Cell Calcium* 44(4):400–410.
51. Ito M, et al. (2008) Difference in Ca²⁺ oscillation-inducing activity and nuclear translocation ability of PLC ζ 1, an egg-activating sperm factor candidate, between mouse, rat, human, and medaka fish. *Biol Reprod* 78(6):1081–1090.
52. Tachibana M, et al. (2013) Human embryonic stem cells derived by somatic cell nuclear transfer. *Cell* 153(6):1228–1238.
53. Kimura Y, et al. (1998) Analysis of mouse oocyte activation suggests the involvement of sperm perinuclear material. *Biol Reprod* 58(6):1407–1415.
54. Wu AT, et al. (2007) PAWP, a sperm-specific WW domain-binding protein, promotes meiotic resumption and pronuclear development during fertilization. *J Biol Chem* 282(16):12164–12175.
55. Aarabi M, et al. (2014) Sperm-derived WW domain-binding protein, PAWP, elicits calcium oscillations and oocyte activation in humans and mice. *FASEB J* 28(10):4434–4440.
56. Shamanski FL, Kimura Y, Lavoie M-C, Pedersen RA, Yanagimachi R (1999) Status of genomic imprinting in mouse spermatids. *Hum Reprod* 14(4):1050–1056.
57. Oakes CC, La Salle S, Smiraglia DJ, Robaire B, Trasler JM (2007) Developmental acquisition of genome-wide DNA methylation occurs prior to meiosis in male germ cells. *Dev Biol* 307(2):368–379.
58. Kishigami S, et al. (2006) Epigenetic abnormalities of the mouse paternal zygotic genome associated with microinsemination of round spermatids. *Dev Biol* 289(1):195–205.
59. Kishigami S, et al. (2006) Significant improvement of mouse cloning technique by treatment with trichostatin A after somatic nuclear transfer. *Biochem Biophys Res Commun* 340(1):183–189.
60. Simerly C, et al. (1995) The paternal inheritance of the centrosome, the cell's microtubule-organizing center, in humans, and the implications for infertility. *Nat Med* 1(1):47–52.
61. Palermo GD, Colombero LT, Rosenwaks Z (1997) The human sperm centrosome is responsible for normal syngamy and early embryonic development. *Rev Reprod* 2(1):19–27.
62. Nakamura S, et al. (2005) A trial to restore defective human sperm centrosomal function. *Hum Reprod* 20(7):1933–1937.
63. Tan SL (1994) Luteinizing hormone-releasing hormone agonists for ovarian stimulation in assisted reproduction. *Curr Opin Obstet Gynecol* 6(2):166–172.
64. Trounson AO, Mohr LR, Wood C, Leeton JF (1982) Effect of delayed insemination on in-vitro fertilization, culture and transfer of human embryos. *J Reprod Fertil* 64(2):285–294.
65. Levron J, Cohen J, Willadsen S (1995) Highly effective method of human oocyte activation. *Zygote* 3(2):157–161.
66. Verheyen G, et al. (1995) Comparison of four mechanical methods to retrieve spermatozoa from testicular tissue. *Hum Reprod* 10(11):2956–2959.
67. Tanaka A, et al. (2009) Metaphase II karyoplast transfer from human in-vitro matured oocytes to enucleated mature oocytes. *Reprod Biomed Online* 19(4):514–520.